ARTICLE IN PRESS

Journal of Pediatric Surgery xxx (xxxx) xxx

Contents lists available at ScienceDirect

Journal of Pediatric Surgery

journal homepage: www.sciencedirect.com/journal/journal-of-pediatric-surgery

Lessons Learned after 176 Patients Treated with a Standardized Procedure of Thoracoscopic Cryoanalgesia during Minimally Invasive Repair of Pectus Excavatum

Luzia Toselli [a, b, *], Cecilia Gigena [a, b], Gaston Bellia-Munzon [a, b], Daniela Sanjurjo [a, b], Maxroxia Vallee [b], Marcelo Martinez-Ferro [a, b]

[a] Fundacion Hospitalaria Mother and Child Medical Center, Av. Crámer 4601. Buenos Aires, C1429AKL, Argentina
[b] Clinica Mi Pectus, Buenos Aires, Argentina. Av. Crámer 4602, Capital Federal, Buenos Aires, C1429AKL, Argentina

ARTICLE INFO

Article history:
Received 4 October 2023
Accepted 14 October 2023

Keywords:
Funnel chest
Cryoablation
Pain management
Chest wall malformation
Nuss procedure

ABSTRACT

Background: Intrathoracic intercostal cryoanalgesia (Cryo) during minimally invasive repair of pectus excavatum (MIRPE) reports have been related to improved pain management, although its extent differs amongst studies. We aimed to report our experience using a standardized perioperative approach including Cryo during MIRPE, and compare our actual results with those of a previous thoracic epidural analgesia (TE) cohort. Lessons learned are summarized.

Methods: Retrospective study including patients undergoing Cryo during MIRPE between October 2018 and May 2023. Results with a standardized perioperative approach were analyzed. We then compared our Cryo cohort with a previous cohort of 62 patients who underwent TE and MIRPE between 2013 and 2018. Continuous variables were reported as mean and standard deviation, and as median (interquartile range) for variables with non-uniform distribution.

Results: We performed 176 Cryo during MIRPE (16.8 ± 4.6 years), with a mean postoperative length of stay (LOS) of 1.4 ± 0.8 days and a median total requirement of 7.5 (0.0; 15.0) oral morphine equivalents (OME) (mg). Patients with Cryo had a significantly lower mean LOS (1.4 ± 0.8 vs. 3.6 ± 1.0 days, $p < 0.0001$), and median total opioid requirement [7.5 (0.0; 15.0) vs. 77.4 (27.0; 115.5 OME (mg), $p < 0.0001$) compared to TE patients.

Lessons learned included ensuring adequate contact of the cryoprobe with the target, proper exposition, and specialized multidisciplinary perioperative patient and family support, including psychology and physical therapy.

Conclusions: In this study, we reported lessons learned after performing a standardized protocol of perioperative care in patients undergoing Cryo during MIRPE. This protocol enabled the achievement of a short LOS and low postoperative opioid requirement.

Type of study: Retrospective comparative study.

Level of evidence: III.

© 2023 Elsevier Inc. All rights reserved.

1. Introduction

Intrathoracic intercostal cryoanalgesia (Cryo) during minimally invasive repair of pectus excavatum (MIRPE) has been shown to reduce hospital stay and the use of opioids [1–5]. However, the extent of improvement reported when compared to other pain management strategies such as thoracic epidural analgesia (TE) is variable [6–11].

Since our first report on Cryo during MIRPE [9], we have consolidated a standardized protocol to enhance postoperative recovery comprised of a series of steps including a multidisciplinary approach, a specialized Cryo technique, a perioperative pain regime, a patient satisfaction evaluation, and a specific Cryo-related complications management.

Given the wide variability of results published after Cryo during MIRPE [6–11], we aimed to report our experience with a standardized

* Corresponding author. Fundacion Hospitalaria Mother and Child Medical Center, Av. Crámer 4601, Buenos Aires, Argentina. C1429AKL. Clinica Mi Pectus. Av. Crámer 4602, Capital Federal, Buenos Aires, C1429AKL, Argentina. Tel.: +541147042380.
E-mail address: dra.luzia.toselli@gmail.com (L. Toselli).

https://doi.org/10.1016/j.jpedsurg.2023.10.047
0022-3468/© 2023 Elsevier Inc. All rights reserved.

Please cite this article as: Toselli L et al., Lessons Learned after 176 Patients Treated with a Standardized Procedure of Thoracoscopic Cryoanalgesia during Minimally Invasive Repair of Pectus Excavatum, Journal of Pediatric Surgery, https://doi.org/10.1016/j.jpedsurg.2023.10.047

Downloaded for Anonymous User (n/a) at Medical University of Lodz from ClinicalKey.com by Elsevier on November 16, 2023. For personal use only. No other uses without permission. Copyright ©2023. Elsevier Inc. All rights reserved.

protocol, compare Cryo results with our prior TE cohort, and the lessons learned along the way.

2. Materials and methods

Retrospective study including patients that underwent Cryo during MIRPE with a standardized protocol aimed at enhancing postoperative recovery in a single institution between October 2018 and May 2023. We described this protocol comprised of a multidisciplinary approach, a specialized Cryo technique, a perioperative pain regime, a patient satisfaction evaluation, and a specific Cryo-related complications management.

We analyze our results with 176 cases including the impact of age by dividing the cohort in pediatric (younger than 18 years old) and adult patients (18 years or older). Also, we compared our findings with a prior consecutive cohort of patients who underwent TE and MIRPE between 2013 and 2018.

Finally, we discuss the lessons learned along the process.

All patients signed a written informed consent for the anonymous use of data. This study obtained IRB approval by the Universidad Abierta Interamericana, Buenos Aires, Argentina (protocol number: 0−1101).

2.1. Perioperative standardized protocol for PE patients undergoing MIRPE and Cryo

2.1.1. Multidisciplinary approach

Our Pectus team comprised specialized pediatric and adult pectus surgeons, physical therapists, psychologists, anesthesiologists, cardiologists, and diagnostic imaging specialists. In terms of pain management, two specialties were considered essential: physical therapy and psychology.

Physical therapists evaluated the patients before and after surgery at our outpatient clinic where they trained them on how to perform abdominal breathing during the immediate postoperative period and provided them with exercises to enhance respiratory and muscular rehabilitation. As inpatients, they visited them and actively stimulated them to leave the bed, walk, and perform optimal breathing exercises.

On the other hand, all patients underwent psychoprophylactic preoperative consultations by a team of specialized psychologists. They performed a series of tests to determine the coping capability of both the patients and their families to be able to undergo surgery and respond to the surgeons' and physical therapists' indications. They also addressed fears and gave them a tour of the facilities to decrease their anxiety.

2.1.2. Technique

We described our MIRPE technique previously [12]. The device used was "Cryo-S Painless"(® METRUM Cryoflex, Blizne Laszczynskiego, Stare Babice, Poland) (Fig. 1).

Regarding operative technique, the following steps were performed (Video 1):

a Selective bronchial intubation with radioscopic guidance.
b Prior to sternal elevation and thoracic remodeling, introduction of the cryoprobe 1 cm medial to the anterior axillary line at the 4th intercostal space (IS) (Fig. 2).
c Identification of the most posterior site of cryoanalgesia in the IS, 3 cm lateral to the sympathetic chain (Fig. 3).
d Application of the tip of the cryoprobe in the middle of the IS with subsequent cephalad pressure (Fig. 4). Application of the cryoprobe on the internal aspect of the rib or longitudinally was avoided (Fig. 5).
e Cryo was performed from the 3rd to 7th IS bilaterally for 2 min at −70 °C.
f Right 30° lateralization of the operating table when operating on the left hemithorax (Fig. 6).

2.1.3. Perioperative pain regime (Table 1)

- Preoperative: PO pregabalin Q8H (3 days 50 mg Q8H, then 4 days 75 mg Q8H).
- In-hospital postoperative: PO pregabalin 75 mg Q8H; IV acetaminophen 1 gr Q8H; IV diclofenac 50 mg Q8H, rescue analgesia IV tramadol 50 mg.

2.1.4. Patient satisfaction evaluation

We used a Visual Analogue Scale to determine the degree of postoperative pain perceived by the patient. It consisted of a scale from 0 (no pain) to 10 (worst pain possible) that was sent via a free cross-platform messaging service on a daily basis for one month since the day of surgery.

Follow-up consisted of visits to the pectus surgeon at one week, two weeks, 1 month, 2 months, 4 months, 1 year, and 2 years when the date of implant removal was scheduled.

2.1.5. Cryo-related complications management

In case neuropathic symptoms presented, including numbness, tingling, burning, stabbing, and shooting pain, frequency and intensity were recorded. If the symptoms were persistent or incapacitating, PO pregabalin 75 mg Q8H was prescribed until complete resolution.

Fig. 1. The cryoanalgesia device used is the "Cryo-S Painless" (® METRUM Cryoflex, Blizne Laszczynskiego, Stare Babice, Poland). Model: thoracoscopic cryoprobe with rounded golden tip 24 k, 30-degree angle, with a 3.0 mm diameter, and a 30 mm length; REF: S06303030.
The cryoprobe cools using high-pressure carbon dioxide allowing a temperature adjustment within a precise therapeutic range. (For interpretation of the references to colour in this figure legend, the reader is referred to the Web version of this article.)

Please cite this article as: Toselli L et al., Lessons Learned after 176 Patients Treated with a Standardized Procedure of Thoracoscopic Cryoanalgesia during Minimally Invasive Repair of Pectus Excavatum, Journal of Pediatric Surgery, https://doi.org/10.1016/j.jpedsurg.2023.10.047
Downloaded for Anonymous User (n/a) at Medical University of Lodz from ClinicalKey.com by Elsevier on November 10, 2023. For personal use only. No other uses without permission. Copyright ©2023. Elsevier Inc. All rights reserved.

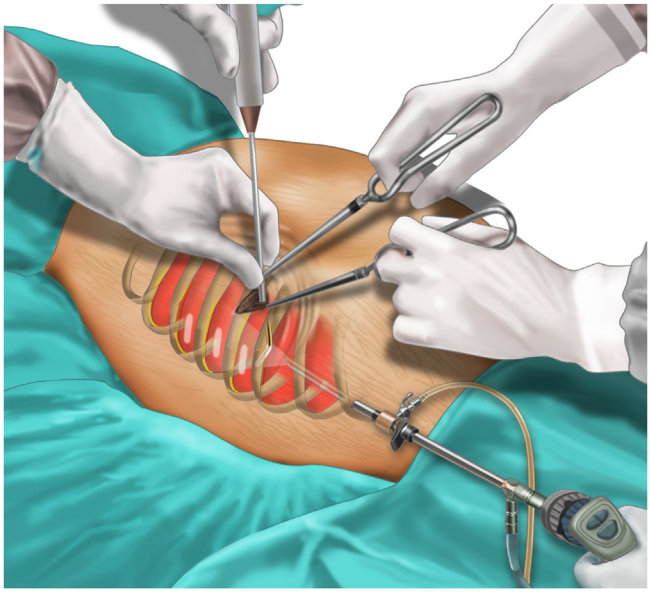

Fig. 2. View of the cryoanalgesia maneuver on the right side, after deflation of the homonymous lung. The cryoprobe enters the right hemithorax through the same incision made for the implants. Note the medial retraction of the incision to introduce the probe through the anterior intercostal space, one centimeter medial to the anterior axillary line.

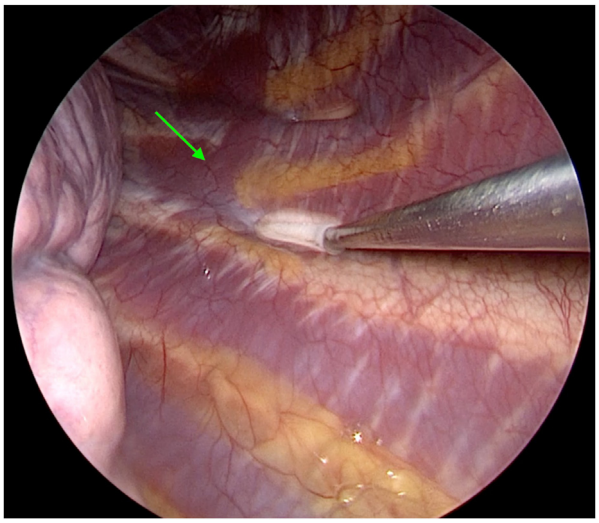

Fig. 3. We freeze the intercostal nerve lateral to the change in the direction of the intercostal muscle fibers (arrow) to avoid injuring the sympathetic chain and, at the same time, reach the intercostal nerve trunk. Complete deflation of the lung and homolateral introduction of the cryoprobe enable such a posterior reach in almost all cases.

2.2. Statistical analysis

Continuous variables were reported as mean and standard deviation, and as median (interquartile range) for variables with non-uniform distribution, whereas categorical variables were reported as frequencies and percentages. Comparisons between groups were performed using independent samples T tests and Mann−Whitney U tests for continuous variables and chi square tests for categorical variables. Statistical analyses were performed using SPSS software, version 22.0 (IBM SPSS Statistics for Windows, Armonk, NY).

3. Results

Between 2018 and 2023, we performed 176 Cryo during MIRPE (93% male; age 16.8 ± 4.6 years). The mean Haller and correction indexes were 5.1 ± 1.7 and 43.3 ± 14.6%, respectively. The mean operative time was 129.2 ± 27.32 min and the mean Cryo-time was 34.6 ± 9.6 min. In the first 5 cases, orotracheal intubation was done until one case in whom we couldn't freeze the last three intercostal spaces (IS) on the left hemithorax due to heart and lung interposition. After that, we transitioned to selective bronchial intubation and were able to complete the 5 IS bilaterally in all cases. There were no postoperative pneumothoraxes requiring surgical reinterventions. The mean postoperative LOS was 1.4 ± 0.8 days. The median total requirement of OME (mg) was 7.5 (0.0; 15.0), the median total requirement of OME/kg was 0.14 (0.0; 0.35), and the median OME/kg/day was 0.10 (0.0; 0.29). Seventy-seven patients (43%) did not require opioids during their hospital stay. There were no readmissions due to uncontrolled pain. Three patients (0.02%) required pregabalin for neuropathic pain with complete resolution after a median of 3 weeks. The self-administered Visual Analogue Scale of pain was of 3.7 ± 2.5 on day 0 and progressively decreased being of 2.1 ± 1.5 by day 7 postoperative (Table 2).

Furthermore, we compared the Cryo cohort with a prior cohort of PE patients undergoing MIRPE with the same type of implants but using TE as part of their pain management strategy (Table 3). We found that the number of implants per patients was higher (Cryo: 2.6 ± 0.5 vs. TE: 2.45 ± 0.7 implants, $p = 0.05$) and the surgical time was longer in the Cryo group (Cryo:129.2 ± 27.3 vs. 113.5 ± 38.3 min, $p = 0.01$). However, LOS was shorter (Cryo: 1.4 ± 0.8 vs. TE: 3.61 ± 1.0 days, $p < 0.0001$) whereas the total narcotic requirement was a median 10 times lower [Cryo: 7.5 (0.0; 15.0) vs. TE: 77.4 (27.0; 115.5) OME (mg), $p < 0.0001$] and the median OME/kg was 9 times lower [Cryo: 0.14 (0.0; 0.35) vs. 1.21 (0.42; 1.85) OME/kg, <0.0001]. Overall, the number of patients who required opioids was significantly lower in the Cryo group [Cryo: 99 (57%) vs. 50 (81%), $p = 0.0015$].

Postoperative complications requiring reoperation were similar in both groups [Cryo:13 (7%) vs. 8 (13%), $p = 0.19$].

We then discriminated our population between pediatric ($n = 135$, 14.9 ± 1.34 years) and adult patients ($n = 41$, 23.4 ± 1.6 years) (Table 4). While their severity indexes were similar, the number of implants was higher (2.6 ± 0.5 vs. 2.8 ± 0.4 implants per patient, $p = 0.002$) and the operative time 15 min longer (140.2 ± 27.7 vs. 125.9 ± 26.4 min, $p = 0.003$) in the elder group. There was a trend towards a longer mean LOS in adults (children: 1.1 ± 1.4 vs. adults: 1.6 ± 1.2, $p = 0.051$). Adults required more narcotics than children although this didn't convey statistical significance [adults: 15.0 (0.0; 18.8) total OME (mg) and 0.25 OME/kg vs. children: 7.5 (0.0; 15.0) total OME (mg) and 0.13 OME/kg, $p = 0.38$ and 0.41]. Postoperative complications requiring reoperation were lower in the pediatric group [children: 7 (5%) vs. adults: 6 (15%), $p = 0.04$]. Of note, there were no reoperations for bar migration or displacement.

4. Discussion

In this study, we analyzed our experience performing Cryo during MIRPE in 176 patients using a standardized protocol to enhance postoperative results. We reported our protocol comprised of a multidisciplinary approach to pain management, a standardized, detailed surgical technique, a perioperative pain regime, patient satisfaction and pain evaluation, and an approach to Cryo-related complications management. Most of our patients were males, teenagers, and received Cryo in 5 intercostal spaces bilaterally. The median total narcotic requirement was low, of 7.5

Please cite this article as: Toselli L et al., Lessons Learned after 176 Patients Treated with a Standardized Procedure of Thoracoscopic Cryoanalgesia during Minimally Invasive Repair of Pectus Excavatum, Journal of Pediatric Surgery, https://doi.org/10.1016/j.jpedsurg.2023.10.047
Downloaded for Anonymous User (n/a) at Medical University of Lodz from ClinicalKey.com by Elsevier on November 16, 2023. For personal use only. No other uses without permission. Copyright ©2023. Elsevier Inc. All rights reserved.

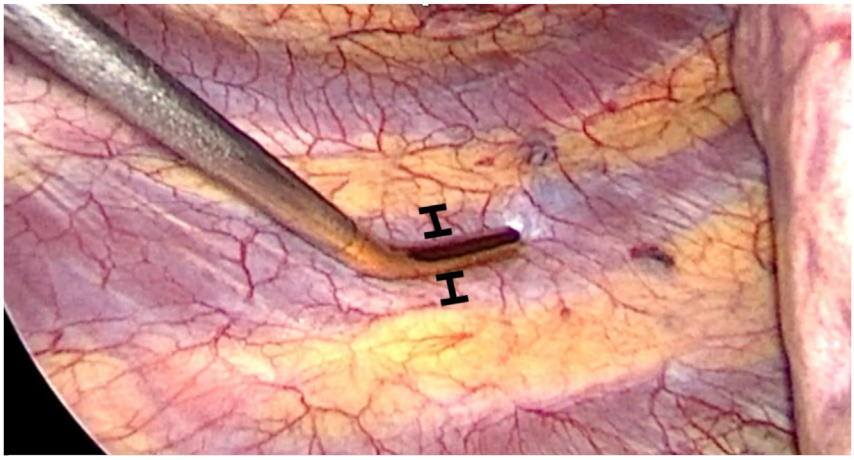

Fig. 4. To achieve a correct application of the entire length of the gold tip of the cryoprobe on the intercostal nerve, the tip must be placed in the middle of the intercostal space, equidistant from both ribs and then pushed cephalad. (For interpretation of the references to colour in this figure legend, the reader is referred to the Web version of this article.)

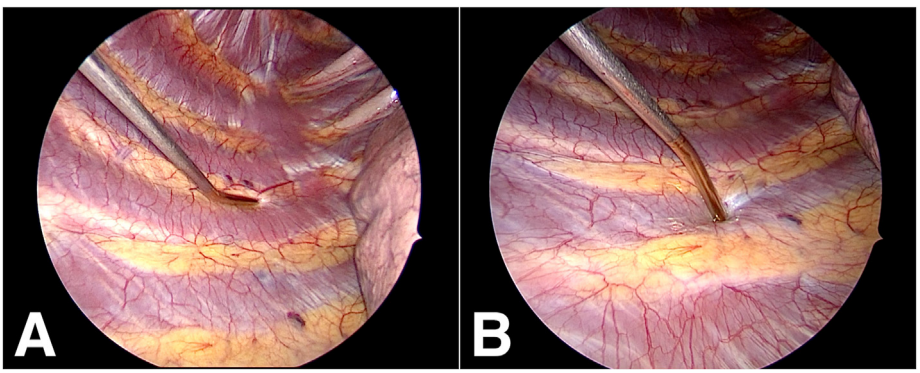

Fig. 5. Errors when performing thoracoscopic intercostal cryoanalgesia. A: Cryoprobe applied on the upper rib of the space. B: Cryoprobe applied vertically on the upper rib.

OME (mg) and the OME/kg of 0.14. Their mean LOS was 1.4 ± 0.8 days postoperative, and the mean Visual Analogue Scale score was 2.8 ± 1.7 at the 3rd day postoperative. When comparing our pediatric versus our adult MIRPE and Cryo cohorts (mean age: 14.9 ± 1.3 vs 23.4 ± 1.6 years) we found there were no statistical differences in opioid requirements and, although LOS showed a trend towards more days in the elder group, it didn't exceed beyond the first postoperative day. Later, we compared our results with our prior MIRPE cohort using TE for postoperative pain management, there was a 10-fold decrease in opioid requirements from 7.5 (0.0; 15.0) to 77.4 (27.0; 115.5) OME (mg), $p < 0.0001$ and a decrease in LOS from 3.6 ± 1 to 1.4 ± 0.8 days postoperative ($p < 0.0001$).

Our results are in keeping with previous studies showing that cryoanalgesia outperforms other postoperative pain management schemes during MIRPE, a particularly painful surgery, in terms of opioid requirement and LOS. Of note, almost half of our Cryo patients did not require any postoperative opioid administration, the highest percentage reported yet. Our study, also suggests that results of this technique in adults might be as good as in children, despite their intrinsic greater chest wall rigidity. For this reason, in the last year, our group has decided not to perform MIRPE in adults older than 20 years old unless Cryo is performed as well.

Other studies have compared Cryo during MIRPE against other pain management strategies. Keller et al. [2] evaluated 26 MIRPE with Cryo and 26 MIRPE with TE between 2013 and 2016. They were the first to show that LOS and opioid requirements were lower with Cryo (3.47 vs. 5.79 days and 49.03 vs. 119.8 mg of opioids). Later on, Harbaugh et al. [3] and Parrado et al. [13], also showed a reduction in opioid requirements when compared with TE or elastomeric pain pumps. One of the studies with the highest level of evidence on the subject was published by Graves et al. [1], a randomized controlled study with 10 patients in each arm showing a decrease in 2 days in LOS and in 416 mg of opioids in the Cryo group versus the TE group. Other groups have published consistent results in LOS and opioid requirement [4,8,14,15] including a twenty-center retrospective cohort study [7]. However, few studies show LOS shorter than 2 days, including Dekonenko et al., Talsma et al., Fraser et al., DiFiore et al., and Rettig et al. with some patients being discharged as early as postoperative day 0 [6,14,16–18].

Using this standardized protocol, we demonstrated consistency in our results in a large cohort of patients, including a very low narcotic requirement and early discharge. Given that pain in the immediate postoperative period is the result of a combination of somatic pain, pressure, fear, and anxiety, we are confident that a multidisciplinary approach is essential to achieve consistent results and the possibility of in-hospital discharge as soon as the first postoperative day with no readmissions for pain control.

5. Lessons learned

1 Selective bronchial intubation for a complete collapse of the lung enables the surgeon to approach ipsilaterally the most posterior aspect of the intercostal space, even in dorsal decubitus. Also, associated with right lateralization of the operative

Please cite this article as: Toselli L et al., Lessons Learned after 176 Patients Treated with a Standardized Procedure of Thoracoscopic Cryoanalgesia during Minimally Invasive Repair of Pectus Excavatum, Journal of Pediatric Surgery, https://doi.org/10.1016/j.jpedsurg.2023.10.047

Downloaded for Anonymous User (n/a) at Medical University of Lodz from ClinicalKey.com by Elsevier on November 16, 2023. For personal use only. No other uses without permission. Copyright ©2023. Elsevier Inc. All rights reserved.

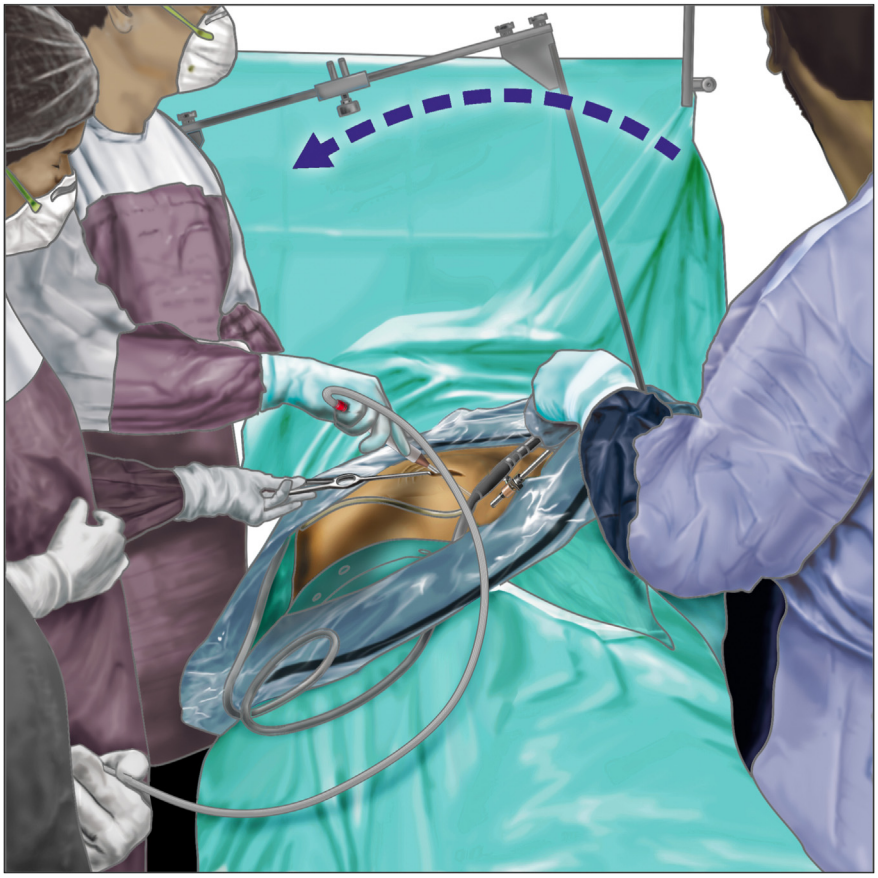

Fig. 6. Before performing left cryoanalgesia, the 5-mm optic is introduced through the 7th or 8th intercostal space and the left anterior axillary line, and the ipsilateral lung is deflated. The operating table is lateralized to the right about 30–45°, moving away the mediastinum that is usually displaced to the left due to sternal sinking.

Table 1
Pain regime for patients undergoing minimally invasive repair of pectus excavatum with thoracoscopic intercostal cryoanalgesia.

Drug	Duration	Pharmaceutical form	Dosis	Frequency	Caution
Preoperative (7 days)					
Pregabalin[a]					
	First 3 days	Tablets (oral)	50 mg	Q8hs	
	Next 4 days	Tablets (oral)	75 mg	Q8hs	Reduce dose if adverse effects (ie. drowsiness)
Postoperative (in hospital)					
Acetaminophen					
	Until discharge	Intravenous	1 gr	Q8hs (interspersed w/diclofenac)	
Diclofenac					
	Until discharge	Intravenous	50 mg	Q8hs (interspersed w/acetaminophen)	
Tramadol					
	Rescue	Intravenous	50 mg	Maximum Q8hs	
Pregabalin[a]					
	Until discharge	Tablets (oral)	75 mg	Q8hs	
Postoperative (out patient)					
Omeprazole					
	4 weeks	Tablets (oral)	40 mg	Q24 hs	
Acetaminophen					
	3 weeks	Tablets (oral)	1gr	Q8hs (interspersed w/ibuprofen)	
Ibuprofen					
	2 weeks	Tablets (oral)	400 mg	Q8hs (interspersed w/acetaminophen)	
Diclofenac					
	Rescue	Tablets (oral)	50 mg	Maximum Q8hs	
Pregabalin[a]					
	Upto 7 days postoperative	Tablets (oral)	75 mg	Q8hs	

[a] Oral gabapentin may be used instead of pregabalin (preoperatively: 3 days 100 mg every 8 hs, next 4 days 200 mg every 8 hs.; postoperatively: 100 mg every 8 hs.).

Please cite this article as: Toselli L et al., Lessons Learned after 176 Patients Treated with a Standardized Procedure of Thoracoscopic Cryoanalgesia during Minimally Invasive Repair of Pectus Excavatum, Journal of Pediatric Surgery, https://doi.org/10.1016/j.jpedsurg.2023.10.047

Downloaded for Anonymous User (n/a) at Medical University of Lodz from ClinicalKey.com by Elsevier on November 16, 2023. For personal use only. No other uses without permission. Copyright ©2023. Elsevier Inc. All rights reserved.

Table 2
Central tendency measurements are shown regarding the Pain Visual Analogue Scale provided to patients with records of the first month postoperative. A reminder messaging system via a free cross-platform messaging service was implemented to increase the response rate.

Postoperative day	Visual analogue scale of pain (mean ± SD)
0	3.7 ± 2.5
1	4.14 ± 2.01
2	3.19 ± 1.76
3	2.77 ± 1.67
5	2.38 ± 1.69
7	2.11 ± 1.53
10	2.17 ± 1.53
14	1.71 ± 1.34
21	1.62 ± 1.6
21 or more	1.47 ± 1.7

table, the left posterior aspect of the intercostal spaces is very well exposed in most cases.

2 Cryo should be performed before sternal elevation and the passing of the retrosternal implants because the pain triggered by the remodeling of the chest wall and the subsequent microfractures is better controlled.

3 Introduction of the cryoprobe 1 cm medial to the anterior axillary line, allows its 30-degree angle golden tip to get completely in contact with the target area. More medial access to the thoracic cavity may risk lung injury and precludes total contact of the tip with the target tissues.

4 Avoidance of positioning the cryoprobe on the upper rib rather than in the middle of the intercostal space with a cephalad thrust is paramount.

5 It is vital to explain to the patient and his/her family the difference between pain and pressure in the postoperative period. As Cryo is applied on the intercostal nerves that conduct somatic sensitivity, the high anterior chest wall pressure sensation they feel is not altered, being maximum in the immediate postoperative period and decreasing rapidly over the next 24–48 h. To reduce confusion between pain and pressure, reassurance by the surgeon, psychologist, and physical therapist enables a prompt discharge.

6. Limitations and future directions

We implemented Cryo in 2018 and since, we have been keen on recording data related to this method. Thus, bias related to researcher interest might have altered patients' results and our efforts to decrease the length of stay and opioid requirements. However, our findings went in line with the literature and bias cannot solely explain the results obtained. Probably the main strength of our work resided in the fact that we developed a protocol that we uniformly implemented from the beginning showing the largest cohort yet published using standardized care in all cases. One of the principal aspects of our protocol was the understanding of the technical issues that may adversely affect Cryo results, issues that have been thoroughly covered in the current work and that have not been analyzed in depth in most studies.

Caution should be taken to extrapolate the results of our comparison between Cryo and TE with other pain management strategies such as IV patient-controlled analgesia.

Of note, pain is a particularly difficult symptom to measure and its intensity is intimately related to the patient and family's coping capabilities. Thus, the subjectivity of the Visual Analogue Scale of pain has not shown to be a very precise tool when trying to determine the effectiveness of Cryo while LOS might be influenced by other factors such as administrative issues or certain populations' expectations. In this sense, future directions include developing and implementing new tools to measure Cryo's efficacy.

Also, randomized controlled studies with large samples and long-term investigations may still be necessary to render definitive

Table 4
Comparison between pediatric (17 years or less) versus adult (18 years or more) patients undergoing minimally invasive repair of pectus excavatum with cryoanalgesia from 2018 to 2023.

	Adults (n = 41)	Children (n = 135)	p
Haller Index	5.35 ± 1.6	5.03 ± 1.8	0.30
Correction Index (%)	43.0 ± 15.8	43.3 ± 14.1	0.92
Implants per patient (n)	2.83 ± 0.4	2.55 ± 0.5	0.002
Surgical time (min)	140.2 ± 27.7	125.9 ± 26.4	0.003
Cryoanalgesia time (min)	36.4 ± 14.4	34.7 ± 7.6	0.17
Intraoperative complications (n)	1 (2%)	5 (4%)	0.67
Total oral morphine equivalent (OME, mg)	15.0 (0.0; 18.8)	7.5 (0.0; 15.0)	0.38[a]
OME/kg	0.25 (0.0; 0.36)	0.13 (0.0; 0.34)	0.41[a]
Length of stay (hours)	45.4 ± 29.1	39.4 ± 15.2	0.09
Postoperative days to discharge	1.61 ± 1.2	1.05 ± 1.4	0.051
Postoperative complications requiring reoperation (n)	6 (15%)	7 (5%)	0.04

[a] Mann–Whitney U test.

Table 3
Comparison between our 176 patients undergoing minimally invasive repair of pectus excavatum with cryoanalgesia with our prior 62 patients with thoracic epidural. Postoperative complications include those requiring surgical reintervention.

	Cryo (n = 176)	Thoracic epidural (n = 62)	p
Age (years)	16.8 ± 4.6	18.2 ± 5.2	0.06
Haller index	5.11 ± 1.7	5.70 ± 2.5	0.046
Correction Index (%)	43.2 ± 14.5	37.4 ± 14.7	0.009
Implants per patient (n)	2.61 ± 0.5	2.45 ± 0.7	0.050
Surgical time (min)	129.2 ± 27.3	113.5 ± 38.3	0.001
Intraoperative complications (n; %)	6 (3%)	0	0.14
Total opioid requirement (OME) (median; IQR)	7.5 (0.0; 15.0)	77.4 (27.0; 115.5)	<0.0001[a]
OME/kg (median; IQR)	0.14 (0.0; 0.35)	1.21 (0.42; 1.85)	<0.0001[a]
OME/kg/day (median; IQR)	0.10 (0.0; 0.29)	0.31 (0.14; 0.52)	<0.0001[a]
Any opioid use	99 (57%)[b]	50 (81%)	0.0015
Length of stay (hours)	40.8 ± 19.4	91.9 ± 24.6	<0.0001
Postoperative days to discharge	1.39 ± 0.8	3.61 ± 1.0	<0.0001
Postoperative complications requiring reoperation (n; %)	13 (7%)	8 (13%)	0.84

[a] Mann–Whitney U test.
[b] missing values n = 2.

Please cite this article as: Toselli L et al., Lessons Learned after 176 Patients Treated with a Standardized Procedure of Thoracoscopic Cryoanalgesia during Minimally Invasive Repair of Pectus Excavatum, Journal of Pediatric Surgery, https://doi.org/10.1016/j.jpedsurg.2023.10.047

Downloaded for Anonymous User (n/a) at Medical University of Lodz from ClinicalKey.com by Elsevier on November 16, 2023. For personal use only. No other uses without permission. Copyright ©2023. Elsevier Inc. All rights reserved.

evidence that Cryo is safe and superior to other pain modalities used for MIRPE.

7. Conclusion

A standardized protocol to enhance postoperative recovery based on the implementation of Cryo during MIRPE has enabled the achievement of a short LOS and a low postoperative opioid requirement in 176 patients, significantly lower than those achieved in our prior cohort of TE cases. Lessons learned along the way comprise ensuring adequate contact of the cryoprobe and the target, proper target exposition, and specialized multidisciplinary pre and postoperative patient and family support, including psychology and physical therapy.

Disclosure

No conflicts of interest to declare.

Appendix A. Supplementary data

Supplementary data to this article can be found online at https://doi.org/10.1016/j.jpedsurg.2023.10.047.

References

[1] Graves CE, Moyer J, Zobel MJ, et al. Intraoperative intercostal nerve cryoablation during the Nuss procedure reduces length of stay and opioid requirement: a randomized clinical trial. J Pediatr Surg 2019;54(11):2250–6. https://doi.org/10.1016/j.jpedsurg.2019.02.057.

[2] Keller BA, Kabagambe SK, Becker JC, et al. Intercostal nerve cryoablation versus thoracic epidural catheters for postoperative analgesia following pectus excavatum repair: preliminary outcomes in twenty-six cryoablation patients. J Pediatr Surg 2016;51(12):2033–8. https://doi.org/10.1016/j.jpedsurg.2016.09.034.

[3] Harbaugh CM, Johnson KN, Kein CE, et al. Comparing outcomes with thoracic epidural and intercostal nerve cryoablation after Nuss procedure. J Surg Res 2018;231(734):217–23. https://doi.org/10.1016/j.jss.2018.05.048.

[4] Rettig RL, Rudikoff AG, Lo HYA, et al. Cryoablation is associated with shorter length of stay and reduced opioid use in pectus excavatum repair. Pediatr Surg Int 2020:0123456789. https://doi.org/10.1007/s00383-020-04778-x.

[5] Daemen JHT, de Loos ER, Vissers YLJ, Bakens MJAM, Maessen JG, Hulsewé KWE. Intercostal nerve cryoablation versus thoracic epidural for postoperative analgesia following pectus excavatum repair: a systematic review and meta-analysis. Interact Cardiovasc Thorac Surg 2020;31(4):486–98. https://doi.org/10.1093/icvts/ivaa151.

[6] Fraser JA, Briggs KB, Svetanoff WJ, et al. Short and long term outcomes of using cryoablation for postoperative pain control in patients after pectus excavatum repair. J Pediatr Surg 2022;57(6):1050–5. https://doi.org/10.1016/j.jpedsurg.2022.01.051.

[7] Arshad SA, Garcia EI, Bell C, et al. Multicenter assessment of cryoanalgesia use in minimally invasive repair of pectus excavatum. Ann Surg 2022. https://doi.org/10.1097/sla.0000000000005440. Publish Ah.

[8] Sun RC, Mehl SC, Anbarasu CR, et al. Intercostal cryoablation during Nuss procedure: a large volume single surgeon's experience and outcomes. J Pediatr Surg 2021;56(12):2229–34. https://doi.org/10.1016/j.jpedsurg.2021.03.006.

[9] Cadaval Gallardo C, Martínez J, Bellía-Munzon G, et al. Thoracoscopic cryoanalgesia: a new strategy for postoperative pain control in minimally invasive pectus excavatum repair. Cir Pediatr 2020;33(1):11–5. http://www.ncbi.nlm.nih.gov/pubmed/32166917.

[10] Mangat S, Hance L, Ricketts KJ, Phillips MR, Mclean SE. The impact of an enhanced recovery perioperative pathway for pediatric pectus deformity repair. Pediatr Surg Int 2020;36(9):1035–45. https://doi.org/10.1007/s00383-020-04695-z.

[11] Lai K, Notrica DM, McMahon LE, et al. Cryoablation in 350 Nuss procedures: evolution of hospital length of stay and opioid use. J Pediatr Surg 2022. https://doi.org/10.1016/j.jpedsurg.2022.10.051.

[12] Bellia-Munzon G, Martinez J, Toselli L, et al. From bench to bedside: 3D reconstruction and printing as a valuable tool for the chest wall surgeon. J Pediatr Surg 2020;55(12):1–7. https://doi.org/10.1016/j.jpedsurg.2020.07.010.

[13] Parrado R, Lee J, McMahon LE, et al. The use of cryoanalgesia in minimally invasive repair of pectus excavatum: lessons learned. J Laparoendosc Adv Surg Tech 2019;29(10):1244–51. https://doi.org/10.1089/lap.2019.0203.

[14] Dekonenko C, Dorman RM, Duran Y, et al. Postoperative pain control modalities for pectus excavatum repair: a prospective observational study of cryoablation compared to results of a randomized trial of epidural vs patient-controlled analgesia. J Pediatr Surg 2020;55(8):1444–7. https://doi.org/10.1016/j.jpedsurg.2019.09.021.

[15] Perez Holguin RA, DeAngelo N, Sinha A, Shen C, Tsai AY. Cost and outcomes of intercostal nerve cryoablation versus thoracic epidural following the nuss procedure. J Pediatr Surg 2023;(xxxx):1–5. https://doi.org/10.1016/j.jpedsurg.2022.12.011.

[16] Rettig RL, Rudikoff AG, Lo HYA, et al. Same day discharge for pectus excavatum—is it possible? J Pediatr Surg 2022;57(9):34–8. https://doi.org/10.1016/j.jpedsurg.2021.02.007.

[17] Joel Talsma MS, Melanie Kusakavitch BA, Dawon Lee BA, Christoph Niederhauser BA, Barnard Palmer MD, Doruk Ozgediz MD, Olajire Idowu MD, Sunghoon Kim M. Forgotten branch of the intercostal nerve: implication for cryoablation nerve block for pectus excavatum repair. J Pediatr Surg 2023. https://doi.org/10.1016/j.jpedsurg.2023.05.006. Published online.

[18] DiFiore JW, Robertson JO, Chhabada S, et al. Next day discharge after the Nuss procedure using intercostal nerve cryoablation, intercostal nerve blocks, and a perioperative ERAS pain protocol. J Pediatr Surg 2022;57(2):213–8. https://doi.org/10.1016/j.jpedsurg.2021.10.034.

Please cite this article as: Toselli L et al., Lessons Learned after 176 Patients Treated with a Standardized Procedure of Thoracoscopic Cryoanalgesia during Minimally Invasive Repair of Pectus Excavatum, Journal of Pediatric Surgery, https://doi.org/10.1016/j.jpedsurg.2023.10.047

Downloaded for Anonymous User (n/a) at Medical University of Lodz from ClinicalKey.com by Elsevier on November 16, 2023. For personal use only. No other uses without permission. Copyright ©2023. Elsevier Inc. All rights reserved.